

A Cleft Lip and Palate Case With Fraser Syndrome: Case Report and Literature Review

Yarık Damak ve Yarık Dudak İçeren Fraser Sendromu Olgusu: Olgu Sunumu ve Literatürün Gözden Geçirilmesi

© Necip Sefa Özden, © Arda Özdemir, © Nijat Babayev, © Savaş Serel

Ankara University Faculty of Medicine, Department of Plastic Reconstructive and Aesthetic Surgery, Ankara, Turkey

Abstract

Fraser syndrome, which is also known as cryptophthalmos-syndactyly syndrome, is a rare autosomal recessive multisystemic genetic disease. This syndrome was first described in 1962 by Canadian Genetic specialist Fraser. Cryptophthalmos, cutaneous syndactyly, head and neck anomalies, urogenital and central nervous system malformations are the main features. In this case report, a patient with cryptophthalmos, syndactyly, testicular agenesis, craniofacial anomalies and bilateral cleft lip-palate, who was diagnosed with Fraser syndrome, was presented.

Key Words: Fraser Syndrome, Congenital Anomaly, Cleft Lip-Palate

Öz

Fraser sendromu kriptoftalmi-sindaktili sendromu olarak da bilinen ve nadir görülen otozomal resesif multisistemik bir genetik hastalıktır. Bu sendrom ilk kez 1962 yılında Kanadalı genetik uzmanı Fraser tarafından tanımlanmıştır. Kriptoftalmi, kutanöz sindaktili, baş-boyun anomalileri, ürogenital ve santral sinir sistemi malformasyonları bu sendromun ana özellikleridir. Bu olgu sunumunda kriptoftalmi, sindaktili, testiküler agenezi, kraniofasyal anormali ve bilateral yarık dudak-damak patolojilerini barındıran bir Fraser sendromu olgusu sunulmuştur.

Anahtar Kelimeler: Fraser Sendromu, Konjenital Anormali, Yarık Damak-Dudak

Introduction

Fraser syndrome, which is also known as Meyer-Schwickerath syndrome, Fraser-François syndrome, Ullrich-Feichtiger syndrome was initially described by a Canadian genetics specialist named George Fraser in 1962. It is an autosomal recessive disease consisting of head and neck anomalies such as cryptophthalmos, hypertelorism, deafness, outer and middle ear deformities, saddle nose, midline nose clefts, teeth irregularities, cleft palate, and/or lip (1). Other pathologies like larynx stenosis/atresia, clitoromegaly, micropenis, hypospadias, cryptorchidism, vaginal atresia, bicornuate uterus, renal agenesis/hypogenesis, syndactyly, wide apart nipples, umbilical

anomalies, microcephaly, encephalocele, meningomyelocele can be present in this syndrome (2).

In the literature, it is claimed to have an incidence of 0.043/10,000 live birth and 1.1/10,000 intrauterine dead birth. Less than 100 cases have been reported up to date (3). Fraser syndrome is known to show genetic heterogeneity according to mutations in *FRAS1* (4q21) and *FREM2* (13q13.3) genes (4). Mutation in the *FRAS1* gene causes disruption in epidermal-basal membrane adhesion and consequently organogenesis. *FREM 2* gene mutation results in structural disruption of *FRAS1* related extracellular matrix protein 2 (5).

In this case report, a Fraser syndrome patient with cryptophthalmos, syndactyly, testicular agenesis, craniofacial

Address for Correspondence/Yazışma Adresi: Necip Sefa Özden

Ankara University Faculty of Medicine, Department of Plastic Reconstructive and Aesthetic Surgery, Ankara, Turkey

Phone: +90 312 595 6148 E-mail: necip.sefa.69@gmail.com ORCID ID: orcid.org/0000-0002-3871-8160

Received/Geliş Tarihi: 04.05.2020 Accepted/Kabul Tarihi: 26.07.2021

©Copyright 2022 Ankara University Faculty of Medicine

Journal of Ankara University Faculty of Medicine is published by Galenos Publishing House.

All content are under CC BY-NC-ND license.



anomaly, and bilateral cleft lip and palate who is operated on, in separate sessions to repair the cleft lip and the cleft palate pathologies is presented.

Case Report

Written informed consent was obtained from parents of this patient. A 2-year-old patient is consulted to our clinic by the pediatric clinic for bilateral cleft lip and palate repair. According to the history taken from the family, the patient is learned to be born weighing 2920 grams from a 25-year-old mother without any prenatal complications at gestational 36th week by C-section. It is also learned that the patient was intubated for 4 months after birth. The family reported that the patient was diagnosed to have bilateral cleft lip and palate and bilateral cryptorchidism by the prenatal ultrasonography yet the patient was not diagnosed to have any syndrome. In history, no mother and father consanguinity was reported. At birth cryptophthalmos, plagiocephaly, hypoplastic nose, hypoplastic ears, bilateral cleft and palate, testicular agenesis were the only pathologies that the patient presented.

On inspection part of the physical examination, by the extraoral examination asymmetrical plagiocephalic head, cryptophthalmos, hypertelorism, flat profiled asymmetrical face, the absence of columella, depressed nose tip with wide nose base, bilateral cleft lip, and anterior displacement of the premaxillary segment were noticed. The front and side views of the patient are shown in Figure 1 and 2.

By the extraoral examination complete cleft palate, multiple missing teeth, enamel hypoplasia, and class 2 occlusion in dentoalveolar angle evaluation. The intraoral view of the patient is shown in Figure 3.

For the assessment of neural and craniofacial development of the patient, a Brain-Orbit magnetic resonance imaging (MRI) was requested. The Brain-Orbit MRI was reported as "Thin corpus callosum, calvarial asymmetry, platybasia, microcephaly, midline defect in the maxilla (cleft palate), the subcutaneous soft tissue in right parietal area in association with bone, a distinction of central canal at the level of the cervical spinal cord, two cystic structures in optic vesicle at right orbit and microphthalmia, cyclical structure belonging deformed primitive globe at left orbit, bilateral lens and optic nerves are not detected". The preoperative MR image of the patient is shown in Figure 4.

For the complete cleft palate repair, von Langenbeck palatoplasty and unilateral cleft lip repair were planned. Complete blood count, full biochemistry, coagulation parameters, and viral markers are requested. No abnormal values were found in the laboratory results. In the preoperative examination of the patient by the department of anesthesia and reanimation cardiac murmur was noticed. Echocardiography of

the patient was requested. The echocardiography was reported as "Left to right shunting through a 1.5-2 mm defect which is thought to be patent foramen ovale".

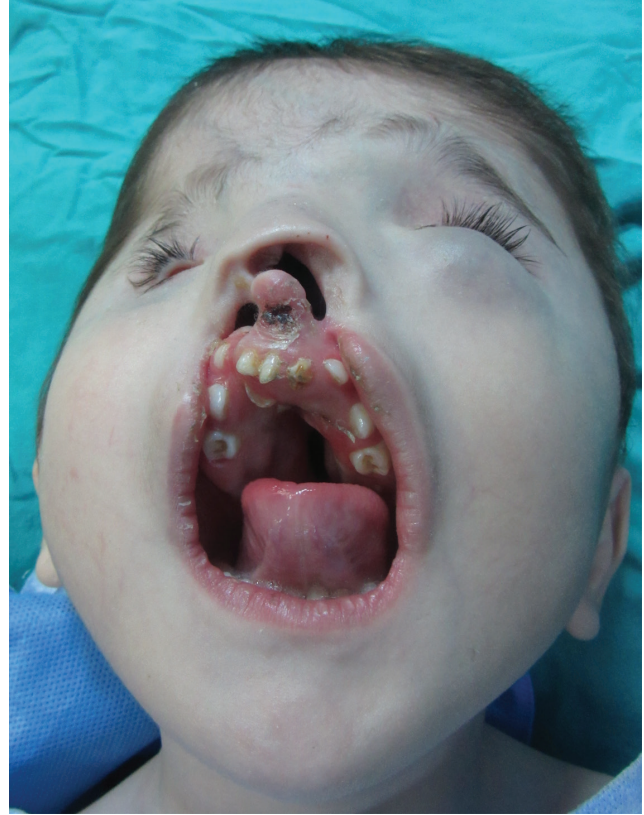

Figure 1: Front view of the patient

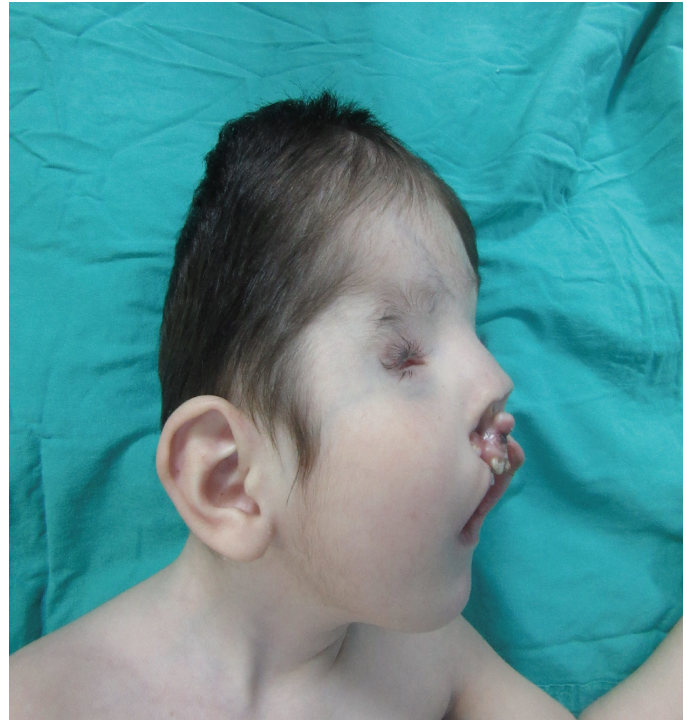

Figure 2: Lateral view of the patient

With an incision medial to alveolar arc to the hamulus notch according to von Langenbeck technique, greater palatine artery-based mucoperiosteal flaps were elevated. Nasal mucosa, soft palate muscles, and oral mucosa were sutured with 4-0 vicryl, 3-0 vicryl, 3-0 rapid vicryl respectively. Afterward for the repair of unilateral cleft lip wedge excision was planned. With the primary repair of the oral mucosa and skin with appropriate sutures, the operation was terminated. The early postoperative views of the patient are demonstrated in Figure 5.

After having oxygen saturations no lower than 94 percent during 3 days in the pediatric intensive care unit and 1 day in the plastic surgery ward the patient was discharged on the postoperative day 4 with appropriate analgesic, anti-inflammatory, and antibiotherapy medication.

Discussion

The clinical findings of our case are consistent with the diagnosis criteria of Fraser syndrome claimed by Thomas et al. (6) The diagnosis criteria and the pathologic clinical findings of our case are stated in Table 1.

van Haelst and Scambler (7) revised the diagnosis criteria for Fraser syndrome in 2007. The revision includes the addition of urinary system anomalies, laryngeal and tracheal anomalies into major criteria. Also minor criteria are revised as anorectal

defects, dysplastic ears, cranial bone defects, umbilical anomalies and nasal anomalies. According to van Haelst and Scambler (7) for the diagnosis of Fraser syndrome two major and 1 minor criteria or 1 major and 4 minor criteria are required. In this case, 2 major criteria of cryptophthalmos and abnormal genitalia, 2 minor criteria of absence of the columella and cranial skeletal defects were present.

Although being one of the minor criteria of Fraser syndrome, there is no statement of the incidence of cleft lip and palate in literature. Migration defect of neural crest cells, apoptotic insufficiency, or a defect in retinoid metabolism are blamed for the pathogenesis of cleft lip and palate even though the pathway is not fully clear (8,9). In this case, bilateral cleft lip and palate were present. Bardach two flaps, Von Langenbeck, Veau-Wardill-Kilner V-Y palatoplasty techniques can be performed for cleft palate repair (10). In this case, von Langenbeck palatoplasty was preferred.

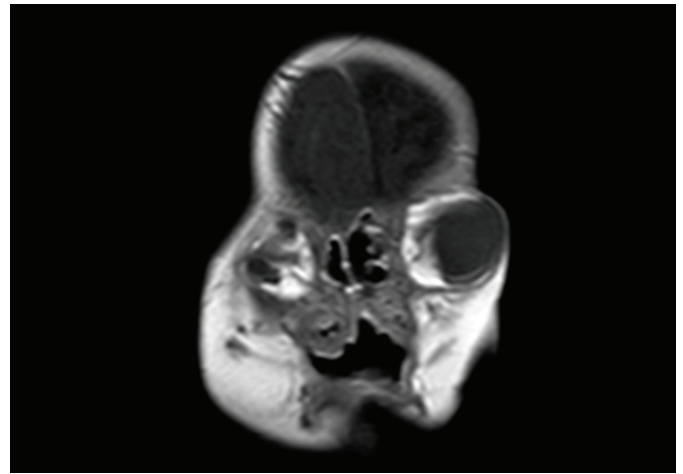


Figure 4: The preoperative MR image of the patient revealing multiple neurologic and skeletal defects

MR: Magnetic resonance

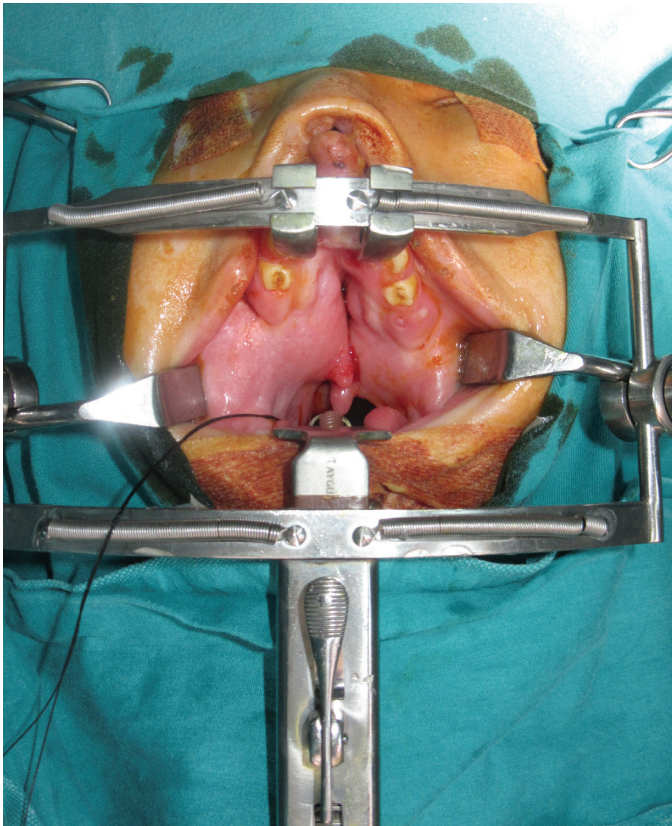


Figure 3: Intraoral view of the patient

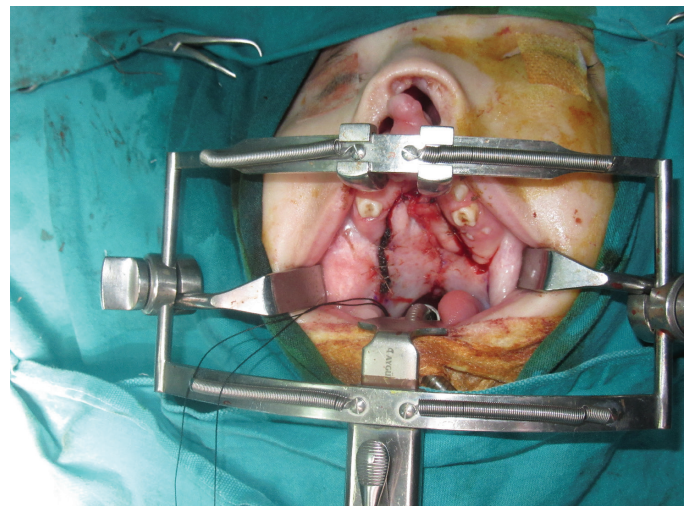


Figure 5: Early postoperative intraoral view of the patient

Cryptophthalmos was described in 1872 by Zehender. It is the most unique finding of Fraser syndrome (11). Yet, Thomas et al. (6) stated that there were not cryptophthalmos in their 14 cases according to their 87 patient Fraser syndrome case series. Cryptophthalmos that can be seen in the syndrome have complete, incomplete, and symblepharon forms. In the complete type which is the most common, eyelids are not formed at all and the forehead skin is continuous with the cheek. The correction of cryptophthalmos requires multiple sessions and in the first session, the Mustardé rotation flap and lower eyelid augmentation with conchal cartilage graft must be performed (12). Afterward, the conjunctiva should be reconstructed with mucosal grafts. In this case, unilateral incomplete cryptophthalmos was present and the reconstruction of the eyelid was planned on a later occasion.

According to Ramsing et al. (13) syndactyly can be seen in 77% of the Fraser syndrome cases. Half of these patients have syndactyly in both hands and feet. Syndactyly in Fraser syndrome is always cutaneous (14). Less than 10% of the patients may also have brachydactyly, nail hypoplasia, and abnormal palmar linings (15). In this case, only syndactyly was present.

Ambiguous genitalia is commonly seen among genital system anomalies. In males, cryptorchidism, micropenis, hypospadias, phimosis, and scrotal hypoplasia can occur. Most common gastrointestinal anomalies include imperforated anus whereas anal stenosis and umbilical hernia are less common (15). In this case, only ambiguous genitalia and none of the gastrointestinal anomalies were present.

Although there is not any case mentioning any cardiac anomalies in the literature review, in this case, patent foramen ovale was detected in echocardiography. Death in Fraser syndrome is generally related to renal agenesis or laryngeal stenosis (11). 25% of the patients are dead at birth, the other 25% die in the first year due to renal agenesis or laryngeal stenosis. 80% of living patients are mentally retarded (11,16). In this case, the patient had mental retardation.

Table 1: Diagnosis criteria for Fraser syndrome stated by Thomas et al. (6)

Major Criteria	Minor Criteria
Cryptophthalmos*	Nasal congenital malformations*
Syndactyly	Auricular congenital malformations
Abnormal genitalia*	Laryngeal congenital malformations
	Cleft lip/palate*
	Skeletal defects
Sibling with Fraser syndrome	Umbilical hernia
	Renal agenesis
	Mental retardation*

(Clinical findings marked with * were present in the case)

Thomas et al. (6) claimed that there is 15% of the patients have a history of mother and father consanguinity. Since the disease has an autosomal recessive transmission it can be said that there is a 25% risk of acquiring this syndrome among siblings. In this case, no known consanguinity was reported. In such cases, it is advised that the families that have a family member of this syndrome get genetic counseling help.

The significance of this case report is that this is the first case report in literature mentioning the repair of cleft lip and palate of a Fraser syndrome patient.

Conclusion

In such cases, with patients having complicated craniofacial anomalies like the one with Fraser syndrome that is mentioned in this case report, the main concern is the general health status of the patient. The functional stability of the facial skeleton should be the second consideration. Last of all concerns, aesthetic results can be considered. After the repair of the cleft lip and palate, the widening of the maxillary arc occurs. The next step is orthognathic surgery including the protrusion of the mandible is followed by the prosthetic replacement of the multiple missing teeth for functional stability and aesthetic coherence.

Also, airway obstructions due to laryngeal stenosis must be carefully examined in these types of syndromic patients. The operations which lengthen the soft palate and narrow the airway such as cleft lip and palate repair must be cautiously planned.

Ethics

Informed Consent: Written informed consent was obtained from parents of patient.

Peer-review: Externally peer-reviewed.

Authorship Contributions

Surgical and Medical Practices: N.S.Ö., S.S., Concept: N.S.Ö., A.Ö., N.B., S.S., Design: N.S.Ö., A.Ö., S.S., Data Collection or Processing: N.S.Ö., A.Ö., S.S., Analysis or Interpretation: N.S.Ö., A.Ö., N.B., S.S., Literature Search: N.S.Ö.; Writing: N.S.Ö., S.S.

Conflict of Interest: We declare that there is no conflicts of interest associated with this publication.

Financial Disclosure: We declare that we have not received any financial support to perform this study.

References

- Sanghani JK, Kamble RH, Shrivastav S, et al. Fraser syndrome without cryptophthalmos: A rare case report. *Journal of Cleft Lip Palate and Craniofacial Anomalies*. 2015;2:139-142.
- Online Mendelian Inheritance in Man, OMIM (TM) 2008. Johns Hopkins University, Baltimore, MD. MIM Number: 219000: Fraser syndrome. <http://www.ncbi.nlm.nih.gov/omim>.

3. Narang M, Kumar M, Shah D. Fraser-cryptophthalmos syndrome with colonic atresia. *Indian J Pediatr.* 2008;75:189-191.
4. Kiyozumi D, Sugimoto N, Sekiguchi K. Breakdown of the reciprocal stabilization of QBRICK/Frem1, Fras1, and Frem2 at the basement membrane provokes Fraser syndrome-like defects. *Proc Natl Acad Sci U S A.* 2006;103:11981-11986.
5. Wood BC, Yi S, Oh AK, et al. Frontal Encephalocele Associated With a Bilateral Tessier Number Three Cleft and Fraser Syndrome. *J Craniofac Surg.* 2015;26:1947-19450.
6. Thomas IT, Frias JL, Felix V, et al. Isolated and syndromic cryptophthalmos. *Am J Med Genet.* 1986;25:85-98.
7. van Haelst MM, Scambler PJ; Fraser Syndrome Collaboration Group, Hennekam RC. Fraser syndrome: a clinical study of 59 cases and evaluation of diagnostic criteria. *Am J Med Genet A.* 2007;143A:3194-3203.
8. Kiran G, Namita G, Dheeraj S. Recurrent Fraser syndrome. *Prenat Diagn.* 2007;27:184-185.
9. Omori M, Chytil F. Mechanism of vitamin A action. Gene expression in retinol-deficient rats. *J Biol Chem.* 1982;257:14370-14374.
10. Agrawal K. Cleft palate repair and variations. *Indian J Plast Surg.* 2009;42 Suppl:S102-S109.
11. Yosunkaya E, Fenercioğlu F, Yüksel A. Fraser sendromu: Bir vaka sunumu. *Fırat Tıp Dergisi.* 2009;14:274-279.
12. Saleh GM, Hussain B, Verity DH, et al. A surgical strategy for the correction of Fraser syndrome cryptophthalmos. *Ophthalmology.* 2009;116:1707-1712. e1.
13. Ramsing M, Rehder H, Holzgreve W, et al. Fraser syndrome (cryptophthalmos with syndactyly) in the fetus and newborn. *Clin Genet.* 1990;37:84-96.
14. Slavotinek AM, Tifft CJ. Fraser syndrome and cryptophthalmos: review of the diagnostic criteria and evidence for phenotypic modules in complex malformation syndromes. *J Med Genet.* 2002;39:623-633.
15. Kılınç N, Demir S, Demir B. Fraser Sendromu: İki Olgu Bildirimi. *Medical Bulletin of Haseki/Haseki Tıp Bulteni.* 2015;53:273-276.